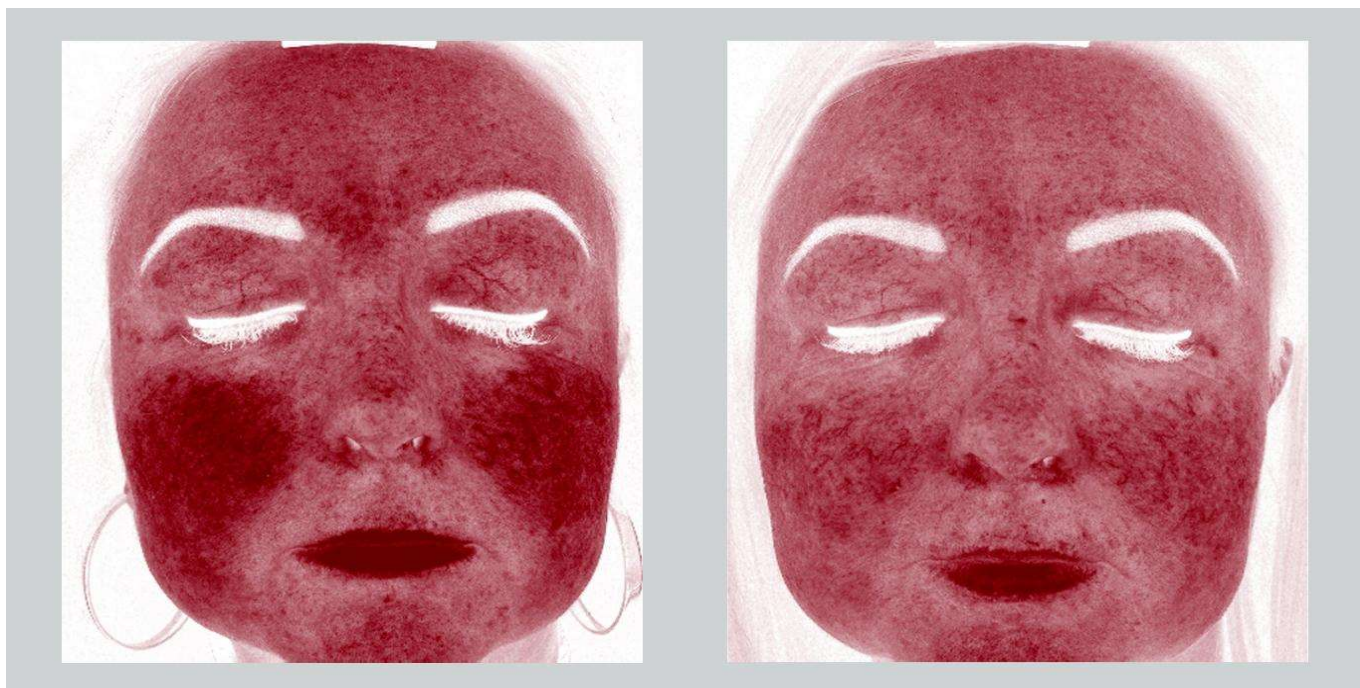

## THE USE OF A VASCULAR LASER KTP - CUTERA EXCEL V IN THE TREATMENT OF VASCULAR CHANGES IN THE COURSE OF ROSACEA – A CASE REPORT.

Piotr Zawodny<sup>1</sup>, Wiola Kuszlewicz<sup>1</sup>, Elzbieta Stoj<sup>1</sup>, Nicole Ciula<sup>1</sup>, Jerzy Sienko<sup>2</sup>

1. Medical Center Klinika Zawodny, Poland

2. Department of General Surgery and Transplantation, Pomeranian medical University, Szczecin, Poland

**#Corresponding author:** Jerzy Sienko MD, PhD, Associate Professor, Department of General Surgery and Transplantation, Pomeranian Medical University, Powstancow Wlkp. Av 72, p.o. box 70-11 Szczecin, Poland, e-mail: jsien@poczta.onet.pl

<b>RUNNING TITLE</b>	KTP laser for treatment of rosacea
<b>KEYWORDS</b>	rosacea; vascular laser; vascular changes; telangiectasia; erythema
<b>WORD COUNT</b>	2083
<b>CONFLICT OF INTERESTS</b>	no conflicts of interest

### ABSTRACT

The Rosacea is a chronic skin disease with an inflammatory nature. It is estimated that this disorder affects women to a greater extent, but it is significantly more severe in men. The Rosacea is predisposed to bright skin with phototype I and II. Symptoms of the disease occur most often in people between 30 and 50 years old. The patient at the age of 39 years, came to the Clinic for the treatment of vascular lesions in the course of the previously diagnosed rosacea of rheumatic-telangiectic type, with dilated blood vessels and accompanying paroxysmal erythema present on the face. In a history showed the type II skin or redness and tightness associated with weather conditions, air conditioning, the family history was also positive. In addition, the patient reported increased burning, itching and redness of the facial skin during severe temperature changes, alcohol consumption and using of the sauna. During the treatment the Excel V laser with a wavelength of 532 nm (KTP) was used. During laser therapy the following parameters: 9.0J/10ms/11mm were used. The scans made by the VISIA diagnostic device show the condition of the blood vessels before and after the period of two months from the first treatment. The visible effects of the laser treatment include a significant reduction of skin erythema, silencing of vascular lesions and unification of the color. The mathematical analysis of VISIA shows a clear improvement in the intensity of household changes by 29%.

## BACKGROUND

The Rosacea is a chronic skin disease with an inflammatory nature [1]. It is estimated that this disorder affects women to a greater extent, but it is significantly more severe in men [2, 3, 4]. The Rosacea is predisposed to bright skin with phototype I and II [2]. Symptoms of the disease occur most often in people between 30 and 50 years of age [2, 5].

The pathogenesis of rosacea has not been yet clearly explained [6, 7]. According to the latest studies on the pathomechanism of rosacea, the key trigger factors is assumed to be the role of the Toll-like 2 receptor and antimicrobial peptides [2, 3]. Other determinants are genetic, hormonal, vascular and sebaceous factors as well as local and general infections. [2, 7, 8]. Not without significance are also environmental factors, such as poor diet, inadequate skin care, psychogenic and atmospheric incentives [6, 8]. Besides, 81-85% of patients have a deterioration of skin condition after exposure to solar radiation [3]. Vascular disorders play a key role in the development of rosacea [6]. The evolution of symptoms is observed, which confirms the nature of the vascular base in the pathogenesis of rosacea. The progress of the disease initiates unstable erythema in the first phase. Then, the period of manifestation of primary symptoms is prolonged and gradually goes into the phase of permanent erythema accompanied by the appearance of telangiectasia [6, 9, 10]. During experimental studies on blood vessels, increased blood flow in patients with established rosacea was observed [9, 11]. There are factors that indirectly affect the overall development of the disease. Stress, menopause, hot drinks, spicy foods or UV radiation are the causes of the intensification of vascular symptoms and thus deterioration of the skin condition in the course of rosacea [4, 6, 8]. The observations concerning the local  $\alpha$ 1-adrenergic receptor agonists under the influence of which erythema is extinguished are also indicative of excessive reactivity of blood vessels. [12]. Patients also have increased expression of markers, which are responsible for stimulating neovascularization. These include the platelet-endothelial adhesion molecule (PECAM1), endothelial growth factor (VEGF) and the marker of lymphoid endothelial cells (D2-40) [4, 13]. The phenomenon of the increase in the expression of the above-mentioned markers indicates the stimulation of blood vessel and lymphatic proliferation. [4, 14]. Neovascularization that is observed in patients suffering from rosacea, also affects the activity of cathelicidin (a proteinaceous antibacterial agent) inducing endothelial cells in various mechanisms [4, 14].

The classification and grades of rosacea were developed in April 2002 by the National Rosacea Society Expert Committee and are based on the morphology of skin changes. Based on these changes, four subtypes of the disease were adopted:

- erythematous-teleangiectatic (ETR),
- papulo-pustular (PPR),
- hypertrophic (PhR)
- ocular (OR) [15, 16, 17]

The course of each of these subtypes can be mild, moderate or severe. Primary eruptions, which include paroxysmal or persistent erythema, telangiectasias, pustules and papules, are scored on a scale of 0-3 depending on the severity. Secondary lesions (erythema-inflammatory foci with visible pustules and papules, burning, edema, hypertrophic changes, dryness, ocular symptoms) are systematized as present or absent [16].

The eruptive erythema, the presence of which indicates the sensitive skin, is considered to be the initial phase of the erythema-telangiectatic form of rosacea. According to the CERIES classification (Epidermal and Sensory Research and Investigation Center, France), four types of sensitive skin are distinguished:

- type I - erythema caused by stress, temperature changes, diet, alcohol,
- type II - erythema and feeling of tightness related to weather conditions, air conditioning,
- type III - erythema, tingling and feeling of tightness as a reaction to a given cosmetic,
- type IV - redness of the skin, hot flushes associated with menstruation [3].

The erythematous-telangiectatic form is the most common variant of rosacea. Characteristic skin changes are recurring or permanent erythema. Accompanying symptoms such as burning, pain, telangiectasias are also observed. Erythema-telangiectatic changes may occasionally also affect areas other than the face, such as the earlobe, neck, chest, hairy skin of head, periphery of the face [3].

## CASE REPORT

The patient (39 years of age) was admitted to the Clinic with dermatological diagnosed ETR type of rosacea. Disease was present on the face (dilated blood vessels and accompanying erythema).

Skin characterization: type II, redness and tightness associated with weather conditions, air conditioning, positive family history. In addition, the patient reported increased burning, itching and redness of the facial skin during severe temperature changes, alcohol consumption and using of the sauna.

During the treatment the Excel V laser was used (wavelength of 532 nm; KTP). During laser therapy the following parameters were used: 9.0J/10ms/11mm.

Scans made by the VISIA diagnostic device, show the condition of the blood vessels before and after the period of two months from the first treatment (Figure 1).

The mathematical analysis of VISIA shows a clear improvement in the intensity of household changes by 29% and by 15% for the patient base of the system (Table 1).

## DISCUSSION

In 1812, Dr. Thomas Batheman made a statement about the incurability of rosacea and this thesis is valid until today. However, there are many methods to maintain remission. The first step to take therapeutic action is to determine the form of rosacea. This is important due to differences in responses to individual therapeutic

strategies [2, 18]. The most problematic in terms of treatment is the erythematous-telangiectatic form, while papule-pustular erythrocythrophy is best responding to local and systemic pharmacotherapy [2]. The simplest basic division of therapeutics are locally and orally admitted medications, the choice of which depends on many factors, such as the subtype of the disease or the severity of symptoms [8]. In the treatment of vascular changes, laser light therapy is beneficial. It is used to reduce paroxysmal erythema, fixed telangiectasia and has a positive effect on the prolongation of the remission period. For therapeutic purposes, intense laser light (IPL) is used, which oscillates in various lengths (515-1200 nm). Depending on the individual predisposition of the patient's skin, the appropriate filter is selected. During the treatment of rosacea, also a pulsed dye laser is used. Besides, a CO2 laser is used to treat hypertrophic changes. Therapy using laser light has a positive therapeutic effect, although the effect of treatment depends on the individual predispositions and the phase of the disease [4, 19].

Essential to therapy is to avoid triggering/intensifying factors that can significantly contribute to exacerbation of clinical symptoms.

In the treatment of vascular changes, the Cutera Excel V laser was used to emit a laser beam with two different wavelengths (KTP 532, ND-YAG 1064 nm). The laser is equipped with a CoolView head with a sapphire cooling window - used to treat veins, telangiectasia and other vascular lesions. These types of lasers are used to treat vascular changes through selective photothermolysis, or selective action on hemoglobin, limiting the thermal damage to the surrounding tissues. In vascular procedures, laser generates the heat which stimulates photocoagulation and leads to the destruction of the blood vessel walls, thus preventing their recanalization [20]. The design of the Laser Cutera Excel V device allows effective treatment of many diseases, including: rosacea, telangiectasias, flat and cavernous hemangiomas, erythema, pigmented changes, scars and viral warts [21].

In the diagnostics (qualitative and quantitative assessment) of vascular changes, the Canfield VISIA device designed for the analysis of skin condition was used. Based on the pictures and numerical values, we are able to plan a personalized treatment schedule (including home care). VISIA has a proprietary RBX technology that provides the ability to analyze the state of the blood vessels under the surface of the skin, which stain red (melanin in contrast is staining brown). The wavelength used in UV photography is 365 nm. The test is fast and completely painless. The doctor performs a skin scan from the hairline to the chin using a digital device. It allows automatic detection of the patient's skin type to improve analysis. The device analyzes the skin structure, pore size, the presence of dilated blood vessels as well as the presence of porphyrins and skin pigmentation. Specialistic examination allows to diagnose the quality and quantity of vascular changes. One of the most important applications of the VISIA device is comprehensive analysis of skin lesions that are the result of UV radiation. The computer program presents the intensity of defects caused by the action of

UV rays, which over the years may cause skin cancer. The device has the ability to simulate the photoaging process. There is a possibility to visualize how the patient will look over the course of 5-7 years, after removing discoloration and wrinkles. VISIA's patented comparison with the standards analysis, which uses one of the world's largest skin characteristics databases to assess the patient's skin compared to other people of the same age who have the same skin type, is also a great help [22, 23, 24].

## CONCLUSION

1. Analysis of the patient's skin, after a period of two months from the first treatment with the Cutera Excel V laser, showed visible effects: significant reduction of skin erythema, silencing of vascular lesions and unification of the color.
2. The mathematical analysis of VISIA shows a clear improvement in the intensity of household changes by 29% and by 15% for the patient base of the system.

## CITE THIS AS

MEDtube Science Mar, 2019, Vol. VII (1), 32 – 35

## ABBREVIATIONS

**CERIES** – Epidermal and Sensory Research and Investigation Center  
**ETR** – erythematous-teleangiectatic  
**KTP** – titanium-potassium phosphate (KTiOPO 4)  
**ND-YAG** – neodymium-doped yttrium aluminum garnet  
**OR** – ocular  
**PECAM1** – platelet-endothelial adhesion molecule  
**PhR** – hypertrophic  
**PPR** – papulo-pustular  
**UV** – ultraviolet  
**VEGF** – endothelial growth factor

## REFERENCES

1. Arasiewicz H, Szilman P, Brzezińska-Wcisło L. Demodex folliculorum in rosacea, based on the generated standard biopsy of the skin surface, Red. Borgis - Advances in Medical Sciences 2015; 3: 177-180.
2. Korting HC, Schöllmann C. Current views on the local and general treatment of rosacea. J Eur Acad Dermatol Venereol 2011; 25: 130-137.
3. Placek W, Wolska H. Rosacea - current views on etiopathogenesis and treatment, Dermatological Review 2016; 103(5): 387-399.
4. Robak E, Kulczycka L. Rosacea - contemporary infirmities on pathomechanism and therapy, Progresses of Hig Med Dosw 2010; 64(10): 439-450.
5. Klaus Wolff. Richard Allen Johnson Fitzpatrick's Color Atlas and Abstract from Clinical Dermatology, Red. Mc Graw Hill Education 2013: 8-12.
6. Graham-Brown R, Harman K, Johnstan G. Dermatology Lecture Notes, Red. Wiley-Blackwell 2016: 158-169.

7. Marks R, Motley R. Common Skin Diseases 2008; 3: 22-25.
8. Gallo R, Nardo A, Muto Y. Prevention of rosacea inflammation, J Invest Dermatol 2014; 11: 2728-2736.
9. Izozon L, English J.C. III, Zirwas M.J. Patient rinsing: differential diagnosis, treatment and treatment, J. Am. Acad. Dermatol 2006; 55: 193-208.
10. Nowak P. Rosacea - treatment and care in a dermatological and cosmetic office Aesthetic Cosmetology 2015; 5: 431.
11. Holmes A.D. Potential role of microorganisms in the pathogenesis of rosacea, J Am Acad Dermatol 2013; 69(6): 1025-1032.
12. Sielska H, Seneczko M. Rosacea - unusual forms. Postępy Dermatol., Alergol 2003; 20(6): 374-379.
13. Czarnecka A, Tymiąńska J. Advances in dermatology and allergology, Red. Dermatitis of adults 2005; 3: 156-160.
14. Nally J.B, Berson D.S . Local treatments for rosacea, J. Drugs Dermatol 2006; 5(1): 23-26.
15. Chodorowska G. rosacea - clinical symptoms and therapeutic options, red. Borgis- Advances in Medical Sciences 2015; 3: 204-210.
16. Plewig G. Rosacea. [in] Braun-Falco. Dermatology. W.H.C. Burgdorf, G. Plewig, H.H. Wolff, M. Landthaler (ed.) Ed. II., Czelej Publishing House, Lublin 2010; 1032-1041.
17. Czarnecka A, Tymicka J. Rosacea - clinical forms and treatment. Post. Dermatol Alergol 2005; 3: 154-160.
18. Brzeziński P. Local treatment in rosacea, Via Medica 2010; 4: 263-272.
19. Drobnik A. Mesotherapy - review method, Aesthetic Cosmetology 2014; 1: 39-42.
20. Rho Nk, Kim H, Kim HS. Effective treatment of serpiginosum haemangioma using a novel 532 nm potassium-phosphate laser (KTP) J Dermatol 2014; 41(11): 996-998.
21. Bernstein EF, Noyaner-Turley, Renton B. Treatment of lower limb spider veins with an innovative KTP laser with wavelength of 532 nm, Lasers Surg Med 2014; 46(2): 81-88.
22. Baldwin HE. Systemic therapy for rosacea. Skin Therapy Lett 2007; 12: 1-5.
23. Lehmann P. Rosacea. CME Dermatol 2008; 3(3): 162-179.
24. VISIA® user's manual; last access: 5th Dec 2018. Available at: <https://www.canfieldsci.com/imaging-systems/visia-complexion-analysis/>

### LIST OF THE TABLES

Tab. 1. Mathematical results of the VISIA analysis.

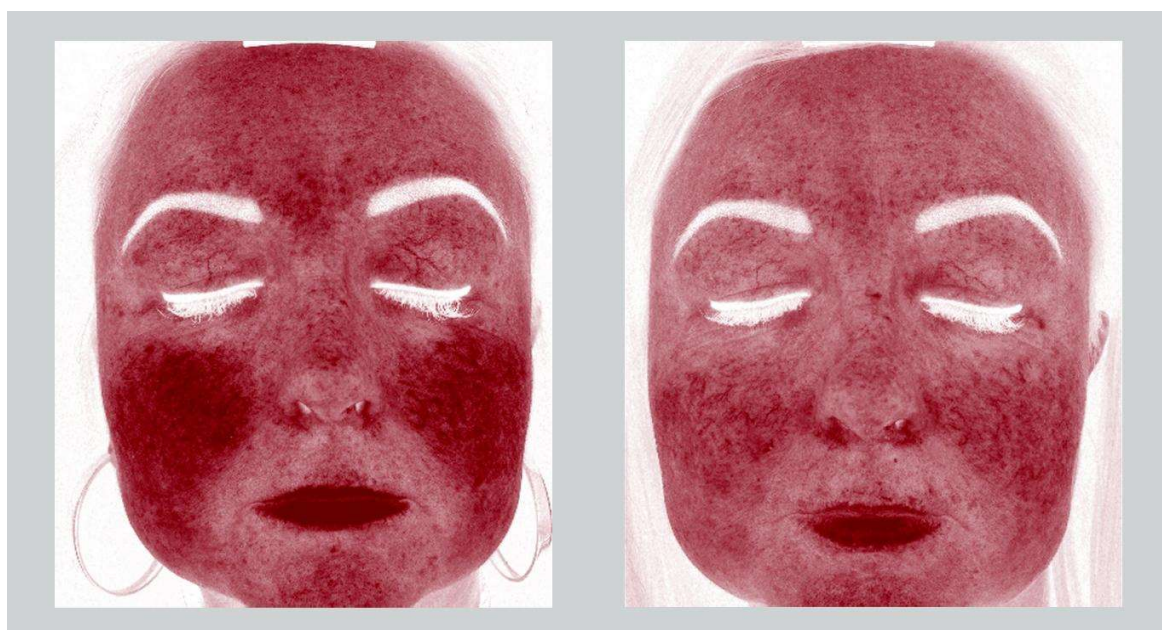
### LIST OF FIGURES

Fig. 1. Scans made by the VISIA diagnostic device, show the condition of the blood vessels before and after the treatment.

**TAB. 1. MATHEMATICAL RESULTS OF THE VISIA ANALYSIS.**

Score	52.191	37.180
Comparative number	1%	16%

**FIG. 1. SCANS MADE BY THE VISIA DIAGNOSTIC DEVICE, SHOW THE CONDITION OF THE BLOOD VESSELS BEFORE AND AFTER THE TREATMENT.**





sharing  
medical  
knowledge™