



Ultrasound to improve the safety of hyaluronic acid filler treatments

Leonie W. Schelke¹ MD | Tom S. Decates¹ MD | Peter J. Velthuis¹ MD, PhD

Erasmus Medical Centre, Department of Dermatology, Rotterdam, The Netherlands

Correspondence: Leonie W. Schelke, Department of Dermatology, Erasmus Medical Centre, Postbus 2040, 3000CA Rotterdam, The Netherlands (lschelke@outlook.com).

Summary

Background: Hyaluronic acid fillers are known for a reliable safety profile, but complications do occur, even serious vascular adverse events.

Objective: To improve the safety of hyaluronic acid filler treatments.

Methods: Ultrasound is used to image hyaluronic acid fillers.

Results: Before a filler treatment is performed with ultrasound, previous filler treatments can be brought in to sight and vascular mapping can be performed. In case of adverse events, the filler and the surrounding tissues are visible. Dislocation, abscesses, and vascular adverse events can be seen. Under ultrasound guidance, hyaluronidase can be injected directly into the filler deposit.

Conclusion: Ultrasound examination can be an important tool to improve the safety of hyaluronic acid filler treatments.

KEYWORDS

complications, cosmetic dermatology, filler, hyaluronic acid, safety, ultrasound

1 | INTRODUCTION

Cosmetic medicine is a continuously growing field, including minimally invasive treatments with resorbable dermal fillers. Hyaluronic acid fillers are the most commonly used products. According to the American Society of Aesthetic Plastic Surgery, over 2.4 million treatments were performed with hyaluronic acid fillers in 2016.¹

As most patients treated are healthy people looking for a cosmetic improvement, the treatments performed should be as safe as possible. Although these fillers are known for a reliable safety profile, adverse events do occur.^{2,3} Complications can be caused by the product itself (too strong cross-linking of the product), the product-host interaction (allergic reactions, inflammatory responses), or the injection technique performed (accumulation or dislocation of the product due to muscle movement, intravascular injection, or vascular compression of filler material).^{3,4} In its most serious form, intravascular injection or vascular compression of

filler material can lead to skin necrosis or, in rare cases, blindness.^{5,6} It has been suggested that the minor signs of vascular compression may be misinterpreted as injection-related bruising, pain, and swelling.⁷

Guidelines and other articles focused on hyaluronic acid fillers are published in order to minimize potential damage to skin and underlying tissue.^{8–11}

Hyaluronic acid fillers come with the advantage of being dissolvable with hyaluronidase in case of complications.¹² If this is necessary, identifying the location of the filler in the skin is important as hyaluronidase should be injected into the filler mass. However, when the filler is placed deep dermally, detection can be very difficult.

Doppler ultrasound (duplex) is commonly used in dermatology to evaluate dermatological conditions of the skin and vascular structures,^{13,14} specifically in the diagnosis of venous disease of the lower leg. Yet, it can also help to improve the safety of hyaluronic acid filler

injections in two distinct ways. First, it is possible to identify the filler in case of a complication.^{15,16} Second, prevention of complications will be improved by locating the important vascular structures and earlier filler treatments in the projected area before a new treatment is performed.

2 | ULTRASOUND FOR FILLERS

An ultrasound device consists of a probe and a processor. The probe will generate a sound wave that penetrates body tissue. Sound waves interact with the tissue and become progressively weaker in strength as the waves are absorbed or scattered. Part of the sound waves is being reflected. The reflected sound waves, picked up by the probe and directed to the processor, are transformed into a digital image. Based on echogenicity Table 1, a filler, or its reaction in tissue, will be imaged as hyperechoic (white on the screen), hypoechoic (gray on the screen), and anechoic (black on the screen). Tissues are isoechoic if they show the same echogenicity as the neighboring tissue, which makes these two tissues indistinguishable.¹⁷

When a Doppler system is integrated with the ultrasound, the device is named duplex. With a duplex machine, blood flow is made visible on the screen in red and blue colors. Herewith, blood vessels can be identified in conjunction with other dermal structures.

Fillers come in different formulae, but they have hydrophilic or hydrophobic characteristics.

All hyaluronic acid fillers are able to bind water and are thus hydrophilic. As water content does not reflect the sound waves, hyaluronic acid appears black (an echogenic) or light gray hypoechoic) on ultrasound Figure 1.¹⁸ The ubiquitously used hyaluronic acid fillers come in different particle sizes, meant for different applications, and are placed in different layers of the skin and subdermis. Depending on the technique, a treading line of multiple dark deposits can be seen, specifically when a cannula is used Figure 1 or a large dark deposit bolus injections for volume replacement) may be visible Figure 2.

3 | ULTRASOUND TO IMPROVE THE SAFETY OF HYALURONIC ACID FILLER TREATMENTS

At our ambulant cosmetic university hospital clinic, we routinely use ultrasound examination to minimize risks, but also to locate and

TABLE 1 Grayscale of echogenicity

Echogenicity	The ability of a tissue or substance to reflect sound waves and produce echoes
Anechoic	No echoes, appears black on ultrasound
Hypoechoic	Less reflective and lower amount of echoes, appears as varying shades of dark gray
Hyperechoic	Highly reflective and echo-rich when compared to neighboring structures, appears as varying shades of light gray
Isoechoic	Having similar echogenicity to a neighboring structure

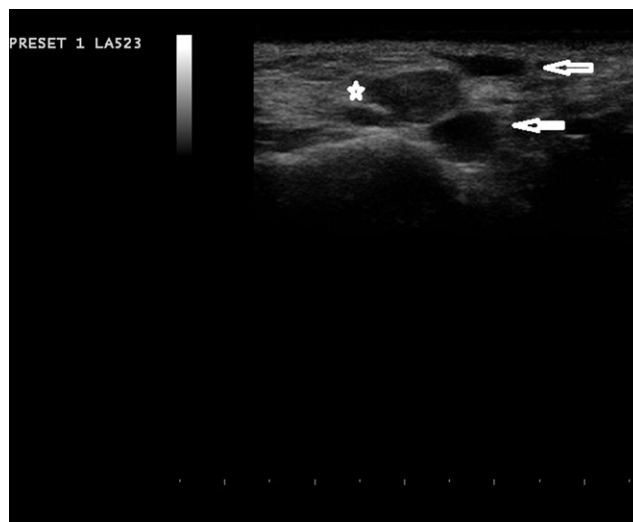


FIGURE 1 Multiple deposits of hyaluronic acid filler, two anechoic deposits (black) and one hypoechoic deposit*

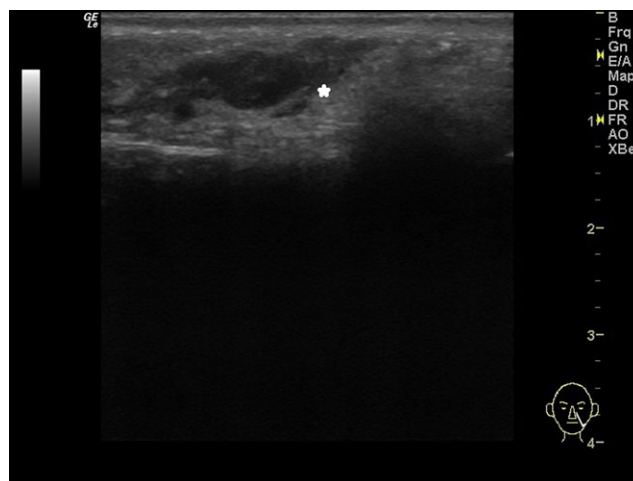


FIGURE 2 Oval-shaped hypoechoic single deposit of hyaluronic acid

identify fillers in patients with side effects who are referred to us. With ultrasound/duplex examination, skin, the underlying tissue including muscles, veins, and arteries can be made visible. At the same time, any filler can be brought into sight, measured in pocket size, and the plane of injection can be seen. We experience that the use of duplex provides an important improvement in the safety of dermal filler treatments.

3.1 | Previous filler treatments

Not only hyaluronic acid but also all fillers are visible with ultrasound.^{15,19} Patients who had previous filler treatments may not always remember the type of filler and the place and plane of injection. Yet, different filler substances may give unwanted side effects,

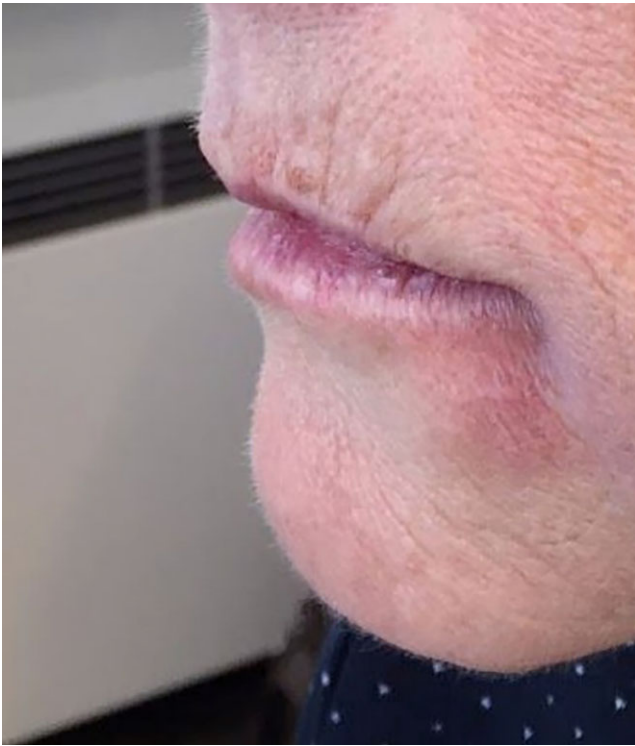

FIGURE 3 Inflammatory response of polymethylmethacrylate after hyaluronic acid filler is injected in the corners of the mouth. Note: the upper lip and chin are also responding

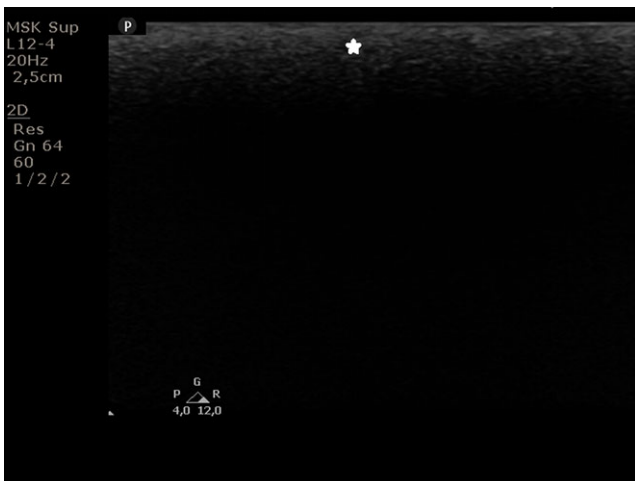


FIGURE 4 Polymethylmethacrylate visible with ultrasound

when mixed. Figure 3 shows the lower face of a 61-year-old woman. She was previously injected with polymethylmethacrylate (PMMA). After a hyaluronic acid filler was injected in the corners of the mouth, she developed an inflammatory response of polymethylmethacrylate (PMMA). The upper lip and chin were also responding with an inflammatory response, although not treated with hyaluronic acid. Using ultrasound before a filler treatment can help to distinguish between the different types of fillers used previously and thus to avoid complications Figure 4.

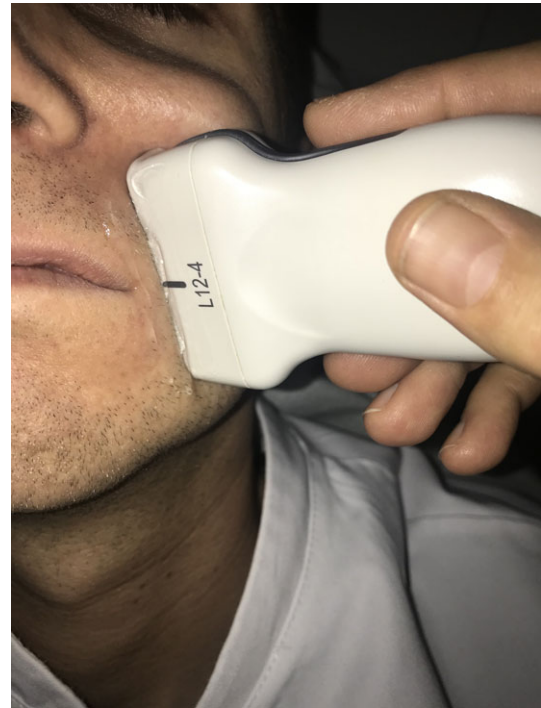

FIGURE 5 Locating artery with duplex

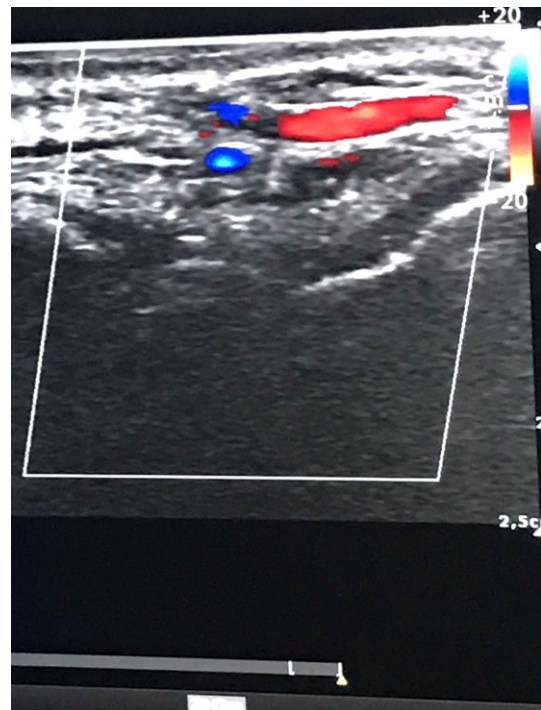


FIGURE 6 Longitudinal view of corresponding artery

3.2 | Anatomical mapping

Serious complications of filler treatments are intravascular injection or vascular compression of filler material leading to skin necrosis or, in rare cases, blindness. As these vessels are not visible clinically, prevention is extremely important. Guidelines advise to use an

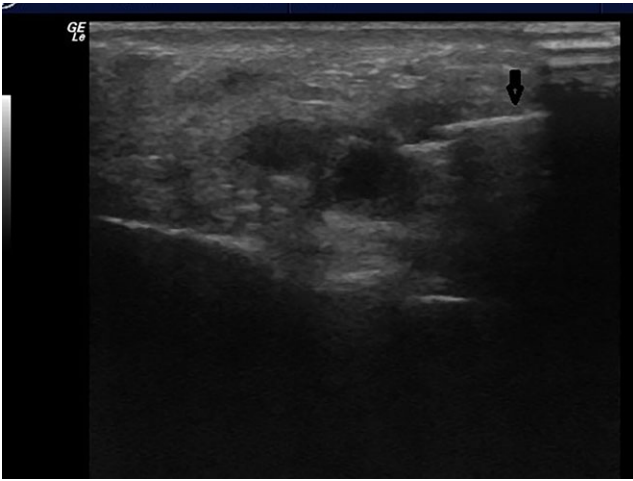


FIGURE 7 Under ultrasound guidance the needle is inserted in the filler deposit top right

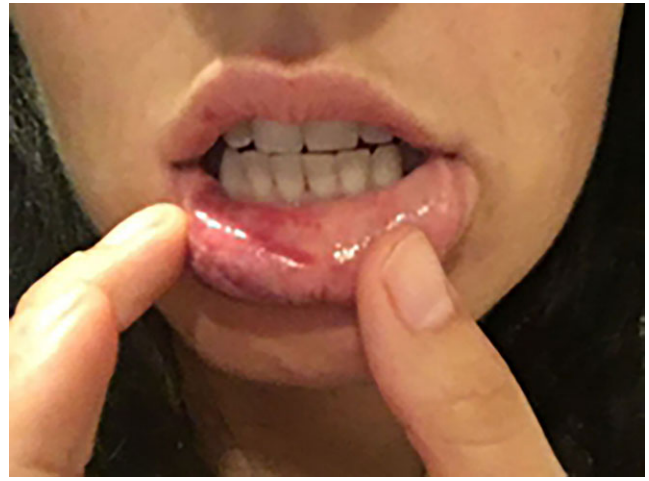

FIGURE 10 Healing of the under lip, no scarring

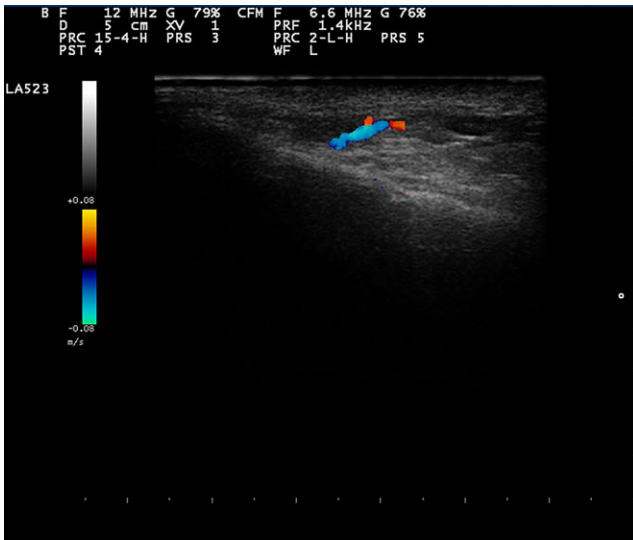


FIGURE 8 Vascular adverse event, hyaluronic acid filler deposit compromises vessel

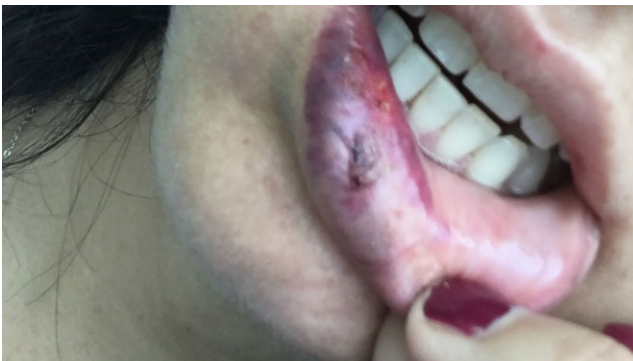

FIGURE 9 Crusting on under lip

adequate injection technique such as cannulas and to inject slowly.^{11,20,21} Most of all, anatomical knowledge of the face and the course of veins and arteries is crucial. Unfortunately, individual variations in facial artery anatomy may exist.^{22,23} Ultrasound allows visualization of the facial arteries and veins of the proposed treatment area and is a noninvasive imaging tool for vascular mapping before the treatment is started.

Vascular structures appear anechoic black, containing liquid) and linear when the transducer is in the same line as the vessel, or circular when the transducer is placed on a section of the vessel. Duplex sonography (B-scan ultrasound combined with color Doppler ultrasound) helps to distinguish structures with movement, for example blood moving within vessels. Color Doppler (blue vs red) can also be used to determine the direction of the blood flow when needed (Figures 5 and 6).

3.3 | Treatment of adverse events with ultrasound

Recently publicized protocols and guidelines describe how to treat unwanted adverse events.²⁴ In our experience, dissolving the filler will terminate most of the adverse events. As mentioned above, hyaluronic acid fillers are easily seen with ultrasound. The pocket size and the location of the filler can be brought into sight. Under ultrasound guidance, hyaluronidase can be injected directly into the filler pocket causing the adverse event (Figure 7).

Dislocation, overcorrection of product, and vascular adverse events can be treated in this way to eliminate the cause of the problem. In case of an inflammatory response, temporary medication as antibiotic treatment may be needed as adjuvant treatment. Special attention is given to vascular adverse events as intravascular injection of filler material or vascular compression (Figure 8) may lead to severe complications as necrosis. The use of ultrasound is very helpful in the treatment of these complications and in the treatment outcome. In Figure 9, the beginning of crusting as a result of a vascular adverse event is seen. This was due to a hyaluronic acid filler treatment in the right lower lip to obtain a lip augmentation. The

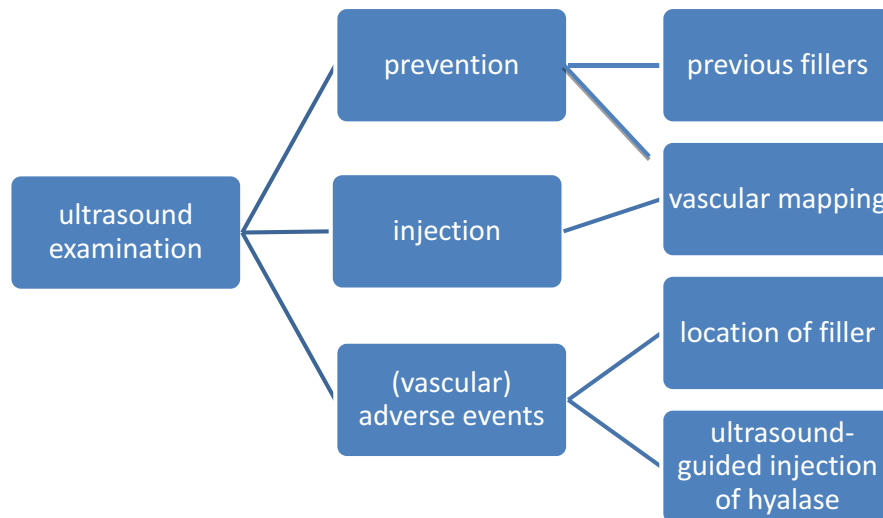


FIGURE 11 Ultrasound examination for filler treatment

referring physician described pain and blanching during injection. Hyaluronidase (150U) was injected once under ultrasound guidance in the hypoechogenic deposit. Immediate improvement was noted by the patient, continuing throughout the day, with complete recovery of her lip Figure 10.

4 | CONCLUSION

Ultrasound examination can be an important tool to improve the safety of hyaluronic acid filler treatments. The amount, location, and depth of the injected hyaluronic acid fillers can be identified. With some practice, it makes a precise intralesional delivery of hyaluronidase possible. As prevention, duplex ultrasound can be used to identify vascular structures in the proposed treatment areas Figure 11.

The learning curve to use and interpret duplex ultrasound pictures is, in our experience, not too steep. Small probes with direct connections to tablets are becoming more and more available for reasonable prices. We feel that these devices should be available in any office of a doctor using hyaluronic acid-based fillers.

CONFLICT OF INTEREST

No conflict of interest disclosures.

ORCID

Leonie W. Schelke  <http://orcid.org/0000-0002-5512-1956>

REFERENCES

1. American Society for Aesthetic Plastic Surgery (ASAPS). *Cosmetic Surgery National Data Bank Statistics*; 2016. <https://www.surgery.org/sites/default/files/ASAPS-Stats2016.pdf>.
2. Artzi O, Loizides C, Verner I, Landau M. Resistant and recurrent late reaction to hyaluronic acid-based gel. *Dermatol Surg*. 2016;42(1):31-37.
3. Vanaman M, Fabi SG, Carruthers J. Complications in the cosmetic dermatology patient: a review and our experience (part 1). *Dermatol Surg*. 2016;42(1):1-11.
4. de Vries CG, Geertsma RE. Clinical data on injectable tissue fillers: a review. *Expert Rev Med Devices*. 2013;10(6):835-853.
5. Lazzeri D, Agostini T, Figus M, et al. Blindness following cosmetic injections of the face. *Plast Reconstr Surg*. 2012;129:995-1012.
6. Kassir R, Kolluru A, Kassir M. Extensive necrosis after injection of hyaluronic acid filler: case report and review of the literature. *J Cos Derm*. 2011;10(3):224-3112.
7. Gilbert E, Hui A, Meehan S, Waldorf HA. The basic science of dermal fillers: past and present part II: adverse effects. *J Drugs Dermatol*. 2012;11(9):1069-1077.
8. Philipp-Dormston WG, Bergfeld D, Sommer BM, Gl S, et al. Consensus statement on prevention and management of adverse effects following rejuvenation procedures with hyaluronic acid-based fillers. *J Eur Acad Dermatol Venereol*. 2017;31(7):1088-1095.
9. Signorini M, Liew S, Sundaram H et al. Global aesthetics consensus: avoidance and management of complications from hyaluronic acid fillers-evidence- and opinion-based review and consensus recommendations. *Plast Reconstr Surg*. 2016;137(6):961e-971e.
10. Carruthers J, Fagien S, Dolman P. Retro or Peribulbar injection techniques to reverse visual loss after filler injections. *Dermatol Surg*. 2015;41(suppl 1):S354-S357.
11. Beleznyay K, Carruthers JD, Humphrey S, Jones D. Avoiding and treating blindness from fillers: a review of the world literature. *Dermatol Surg*. 2015;41(10):1097-1117.
12. Cavallini M, Gazzola R, Metalla M, Vaienti L. The role of hyaluronidase in the treatment of complications from hyaluronic acid dermal fillers. *Aesthet Surg J*. 2013;33(8):1167-1174.
13. Wortsman X, Alfageme F, Roustan G et al. Guidelines for performing dermatologic ultrasound examinations by the DERMUS Group. *J Ultrasound Med*. 2016;35(3):577-580.
14. Wortsman X. Sonography of dermatologic emergencies. *J Ultrasound Med*. 2017;36:1905-1914.
15. Wortsman X, Wortsman J, Orlandi C, Cardenas G, Sazunic I, Jemec GB. Ultrasound detection and identification of cosmetic fillers in the skin. *J Eur Acad Dermatol Venereol*. 2012;26(3):292-301.

16. Grippaudo FR, Di Girolamo M, Mattei M, Pucci E, Grippaudo C. Diagnosis and management of dermal filler complications in the perioral region. *J Cosmet Laser Ther.* 2014;16(5):246-252.
17. Rallan D, Harland CC. Ultrasound in dermatology – basic principles and applications. *Clin Exp Dermatol.* 2003;28:632-638.
18. Kohn JC, Goh AS, Lin JL, Goldberg RA. Dynamic high resolution ultrasound in vivo imaging of hyaluronic acid filler injection. *Dermatol Surg.* 2013;39:1630-1636.
19. Schelke LW, DenElzen HJ, Erkamp PP, Neumann HA. Use of ultrasound to provide overall information on facial fillers and surrounding tissue. *Dermatol Surg.* 2010;36(suppl 3):1843-1851.
20. Casabona G. Blood aspiration test for cosmetic fillers to prevent accidental intravascular injection in the face. *Dermatol Surg.* 2015;41:841-847.
21. Coleman SR. Avoidance of arterial occlusion from injection of soft tissue fillers. *Aesthet Surg J.* 2002;22:555-557.
22. Lee SH, Gil YC, Choi YJ, Tansatit T, Kim HJ, Hu KS. Topographic anatomy of the superior labial artery for dermal filler injection. *Plast Reconstr Surg.* 2015;135(2):445-450.
23. Furukawa M, Mathes DW, Anzai Y. Evaluation of the facial artery on computed tomographic angiography using 64-slice multidetector computed tomography: implications for facial reconstruction in plastic surgery. *Plast Reconstr Surg.* 2013;131(3):526-535.
24. DeLorenzi C. New high dose pulsed hyaluronidase protocol for hyaluronic acid filler vascular adverse events. *Aesthet Surg J.* 2017;37:1-12.

How to cite this article: Schelke LW, Decates TS, Velthuis PJ. Ultrasound to improve the safety of hyaluronic acid filler treatments. *J Cosmet Dermatol.* 2018;17:1019-1024.

<https://doi.org/10.1111/jocd.12726>