

# Deep Orbital Sub-Q Restylane (Nonanimal Stabilized Hyaluronic Acid) for Orbital Volume Enhancement in Sighted and Anophthalmic Orbits

Raman Malhotra, FRCOphth

**Objective:** To describe a new technique of injecting Restylane Sub-Q (Q-Med, Uppsala, Sweden) into the intraconal and extraconal posterior orbit.

**Methods:** Retrospective review. Eight injections were performed in 5 patients using 2-mL Sub-Q in the intraconal and extraconal posterior orbit for orbital volume enhancement. Four injections were performed in sighted orbits and the remaining in anophthalmic orbits. The age range was 18 to 36 years; the follow-up time was 5 to 12 months.

**Results:** Orbital volume enhancement was achieved in all cases with an improvement in upper eyelid sulcus and skin fold. Enophthalmos reduction was 2 mm per 2-mL

injection. The procedure was well tolerated. One patient experienced a vasovagal episode lasting 3 hours and 1 patient had postoperative pain. No such episodes occurred after I began injecting local anesthesia before performing the Sub-Q injection. One patient required hyaluronidase for migrating gel, which caused lower eyelid swelling.

**Conclusion:** This small case series suggested the safety and tolerability of deep orbital Sub-Q. Injections are easily performed in the outpatient setting. The expected volume enhancement was achieved in all cases with no long-term adverse effects to date.

*Arch Ophthalmol.* 2007;125(12):1623-1629

**O**RBITAL VOLUME DEFICIENCY following loss of an eye often persists despite the use of orbital ball or enophthalmic implants, dermis fat grafts, autologous fat injection, hydrogel expanders, or silicon implants.<sup>1-4</sup> Volume enhancement in sighted orbits needs to be safe and easily reversible to minimize risk of sight loss, diplopia, and significant globe displacement. In the age of nonsurgical facial rejuvenation, fillers are an ideal option for orbital volume enhancement because they are easily performed in the outpatient setting, avoiding general anesthesia, and offer a high degree of tolerability and acceptability from patients undergoing dermal filler treatment. Permanent facial fillers have been reported for orbital enhancement in anophthalmic orbits.<sup>5</sup> However, concern still remains regarding the ability to remove such products from the orbit should complications occur.

Restylane (Q-Med, Uppsala, Sweden), a nonanimal stabilized hyaluronic acid (NASHA), was the first hyaluronic-acid product to be approved by the Food and Drug Administration for soft tissue aug-

mentation. Nonanimal stabilized hyaluronic acid offers longer-lasting esthetic effects than bovine collagen or avian hyaluronic acid and potentially lower risks of immunogenicity and hypersensitivity reactions with the added benefit of being dissolved by hyaluronidase.<sup>6,7</sup>

A more viscous, longer-lasting NASHA gel called Restylane Sub-Q was recently introduced; its effects are described as lasting for 1 year.<sup>8-10</sup> The literature from the company shows that Sub-Q contains 1000 molecules/mL compared with 10 000 for Perlane (Q-Med) and 100 000 for Restylane. Larger molecular size increases the thickness and viscosity of Sub-Q compared with Perlane and Restylane with no difference in cross-linking. Herein I describe a new technique of injecting Sub-Q into the intraconal and extraconal posterior orbital cavity.

## METHODS

I present a retrospective case series of 8 injections in 5 patients for orbital volume enhancement using Restylane Sub-Q injected through a single-site inferotemporal transcutaneous peribulbar approach. Four injections were in

**Author Affiliations:**  
Corneo-Plastic Unit, Queen Victoria Hospital, East Grinstead, United Kingdom, and McIndoe Surgical Centre, East Grinstead.

sighted orbits; the remaining 4, anophthalmic orbits. Ages ranged from 18 to 36 years and follow-up from 5 to 12 months. All patients underwent computerized tomography (CT) orbital imaging prior to injection.

The patient was laid 30° supine. The orbit was injected using a primed green 25-gauge needle attached to the Sub-Q Luer-Lok syringe through a standard transcutaneous inferotemporal peribulbar-type approach. I began the injection after the tip was beyond the equator of the globe. While slowly injecting, I carefully advanced the needle in a retrobulbar direction within the inferior orbital space. A standard vial of 2-mL Sub-Q was injected to distribute it medially and laterally as well as a small amount superomedially from the same injection site without withdrawing from the orbit. I made the injection while advancing the needle to theoretically avoid sharp needle-related orbital hemorrhage by hydrodisplacement of vessels during extremely slow needle advancement. The study end points included fullness of upper eyelid and subbrow sulcus and immediate reduction of enophthalmos by approximately 2 mm.

Because of patient discomfort and vasovagal symptoms immediately following injection in cases 2 and 3, in subsequent cases I made a peribulbar injection of 0.5-mL 0.5% bupivacaine with 1:200 000 epinephrine through an inferotemporal transcutaneous approach 15 minutes prior to injecting orbital Sub-Q to minimize any potential oculocardiac reflex symptoms following intraconal injection.

## REPORT OF CASES

### CASE 1

A 29-year-old man requested orbital volume enhancement because of concern over the appearance of progressive deep-set eyes for the last 10 years. His surgeon had commented on the condition during laser-assisted in situ keratomileusis when he found it difficult to carry out the procedure. The patient had sought treatment elsewhere 3 years previously, and surgery was not recommended. He did not report any changes in the appearance of his face, double vision, or sinus-related problems and was otherwise well. On examination, unaided visual acuity was 6/6 OD and 6/5 OS. He had relative enophthalmos with prominent brows creating the appearance of deep-set eyes (**Figure 1A**). Hertel measurements were 13 mm in both eyes with no globe displacement; the patient had full eye movements, no periorbital sensory changes, and a normal dilated retinal examination. An orbital CT scan was normal (**Figure 1B**); however, in the posterior orbital cavity, there appeared a significant enlarged inferior space bilaterally (**Figure 1C**).

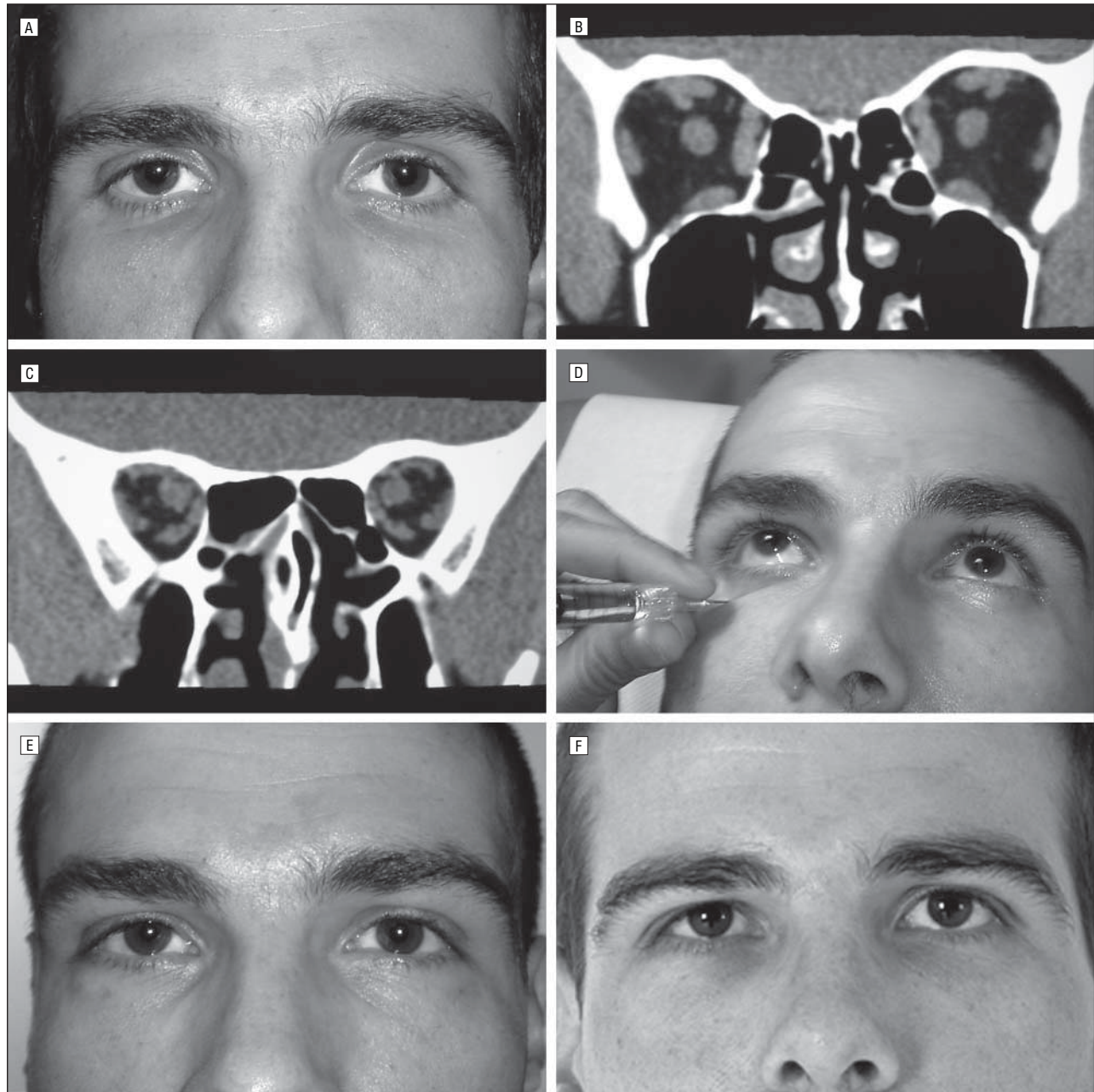
The patient requested bilateral treatment to minimize cost, and because work commitments required him to regularly fly overseas, he could not guarantee he would attend regular follow-up visits in the early postoperative period. Surgical procedures were therefore not recommended, and the use of a temporary filler was suggested. I contacted the company Q-Med, discussed this case with a number of colleagues, and forwarded all communication to the patient to emphasize the new nature of this treatment as well as the lack of any direct evidence of its effect in the orbit and on the eye. He was also made fully aware of the potential risks of surgical and nonsurgical options. The patient then requested bilateral Sub-Q injections for treatment.

The procedure was well tolerated (**Figure 1D**) during the injection, and the patient was aware of a mild ache only. This persisted for 10 to 15 minutes following injection during which time the patient experienced mild vertical diplopia that measured less than 10 prism diopter and that resolved within 3 minutes of the injection. Upper eyelid and subbrow sulcus fullness and immediate reduction of enophthalmos by approximately 2 mm were noted. A right upper eyelid ptosis of approximately 1 mm was also seen; however, the overall esthetic result was acceptable to the patient after he examined his face in the mirror. Vision remained subjectively normal, and after a period of 20 minutes, during which time the patient was given oral paracetamol and symptoms of discomfort and diplopia dissipated, I began the injection to the left orbit. This was carried out in the same manner and was tolerated well. The patient experienced an initial sensation of mild discomfort behind the globe, but it resolved within 5 minutes. No diplopia was noted, and once again, a 2-mm reduction of enophthalmos was visible immediately (**Figure 1E**). Vision remained normal throughout the immediate postoperative period, and repeat Hertel measurements recorded 15 mm in both eyes.

The patient was discharged after an hour of observation. He remained well thereafter and very pleased with the result at 2 days, 1 week, 1 month, and 3 months. Visual acuity, color vision, visual fields, intraocular pressures, and eye movements remained normal throughout follow-up. At 3 months, the patient remained stable with a 2-mm reduction of enophthalmos; however, he requested repeat bilateral treatment to bring his eyes further forward. Aware of the potential for overfill, he consented to repeat sequential bilateral injections in the same session identical to his first treatment. A further 1- to 2-mm reduction in enophthalmos was achieved; however, the injection was targeted at placing the product predominantly in the inferior compartment of the posterior orbit, and intraconal injection was avoided. This immediately gave rise to migration of the product anteriorly and an appearance of a slightly full right lower eyelid. This improved but did not resolve over the next few months, and 4 months later, the patient requested a hyaluronidase injection to his right lower eyelid. Hyaluronidase was injected in the suborbicularis plane with a slight improvement. No reduction in enophthalmos occurred following the injection of hyaluronidase, and a slight fullness in the right lower eyelid remained. Hertel measurements remain reasonably stable with a reduction in enophthalmos of 2 mm at 12 months compared with pretreatment measurements (**Figure 1F**).

### CASE 2

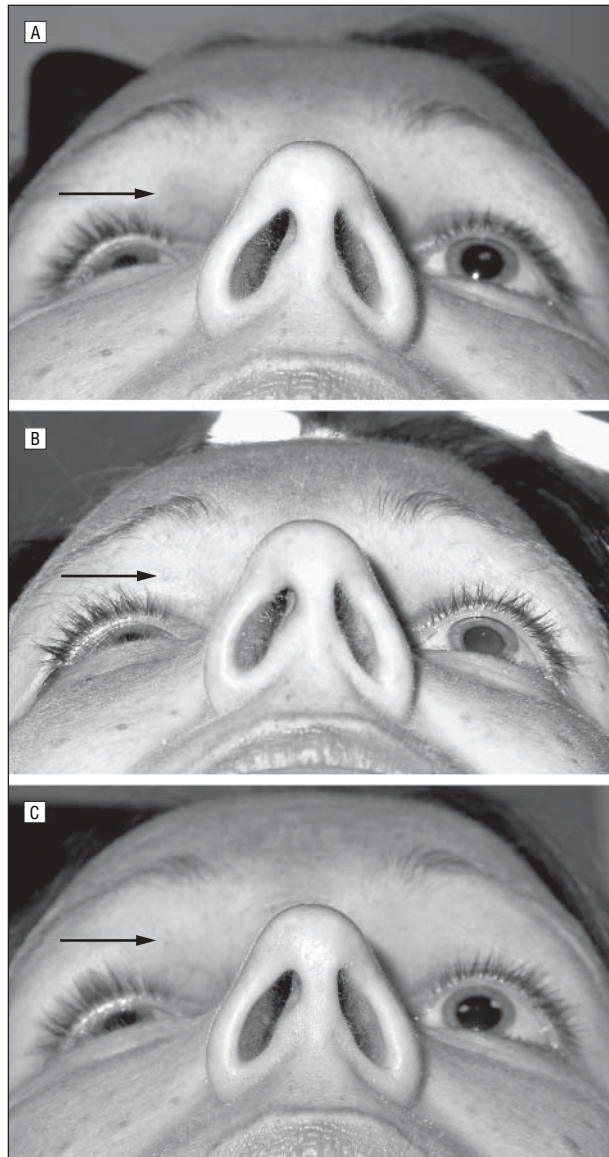
A 30-year-old woman with orbital volume deficiency following enucleation was referred for volume enhancement. Her right eye had undergone enucleation when she was a child after a motor vehicle crash that resulted in multiple facial fractures, including a left orbital roof fracture. She underwent orbital implant surgery with a 22-mm hydroxyapatite ball implant and experienced significant postoperative pain and swelling that lasted for many weeks. Her volume deficiency persisted despite an



**Figure 1.** Images for a 29-year-old male patient in case 1. A, Deep-set eyes with prominent brows. B, Normal coronal soft-tissue window computed tomographic scan. C, Bilateral enlarged inferior space in posterior orbital cavity. D, Orbital Sub-Q injection (Q-Med, Uppsala, Sweden) through a standard transcutaneous inferotemporal peribulbar-type approach. E, Reduction of enophthalmos of 2 mm, immediately seen following injection. F, Stable reduction in enophthalmos at 12 months with fullness of upper eyelid sulcus as well as lower eyelid.

orbital implant (**Figure 2A**) and she requested further treatment; however, she declined an orbital floor implant because of her experience of postoperative symptoms and requested a less invasive approach. Following a fully informed discussion about my experience so far with orbital Sub-Q, she underwent a deep orbital Sub-Q injection. She experienced pain during the slow injection, necessitating that I temporarily stop the procedure. This pain improved within 10 minutes and the procedure was completed with a total of 2 mL injected and a 2-mm reduction in enophthalmos (**Figure 2B**). She continued to experience a dull ache and felt a little faint, but within an hour she recovered and was discharged. On

the night of the procedure, she developed significant pain and swelling, which persisted for the next 2 days. This was not severe enough for her to request an emergency review; however, she felt at the time that it may have represented an orbital hemorrhage. At her 1-week review, she remained well and pain free, and it was thought unlikely that her symptoms were related to orbital hemorrhage. Reduction in enophthalmos of 2 mm was seen at her 6-month follow-up; however, a deep upper eyelid sulcus persisted. Loss of volume was noted at the 9-month follow-up with only a 1-mm reduction in enophthalmos and a deep upper sulcus (**Figure 2C**). The patient requested further treatment but declined a second deep



**Figure 2.** Images for a 30-year-old female patient in case 2. A, Right orbital volume deficiency with enophthalmos and deep upper sulcus (view from below). B, Immediate 2-mm reduction in enophthalmos following right orbital Sub-Q injection (Q-Med, Uppsala, Sweden). C, Slight loss of volume noted at 9-month follow-up with approximately 1-mm reduction in enophthalmos.

orbital injection because of her initial experience. She was scheduled to undergo a Sub-Q injection to the upper sulcus under local anesthesia and mild sedation.

### CASE 3

A 29-year-old man requested treatment for right orbital volume deficiency following enucleation as a teenager because of a motor vehicle crash that resulted in facial fractures and a globe injury. He had previously undergone a secondary ball implant and expressed an interest in exploring nonsurgical options to correct residual facial asymmetry. He underwent a single 2-mL deep orbital Sub-Q injection (as described earlier) as an office procedure. At the time of the injection, he developed mild discomfort and vasovagal symptoms. He felt faint immediately after

the injection with a decrease in blood pressure to 90/50 mm Hg. He was admitted for observation overnight due to vasovagal symptoms of feeling faint that persisted for 3 hours but resolved by the next morning. He did not experience any pain or discomfort during this period and was very pleased with his results the following morning. Once again, a reduction of 2 mm of enophthalmos was achieved along with a fullness in his right upper eyelid and subbrow sulcus. This reduction in enophthalmos remained for 4 months, and a slight reduction remained at 8 months with less than a 1-mm reduction in enophthalmos and partial return of the deep upper sulcus.

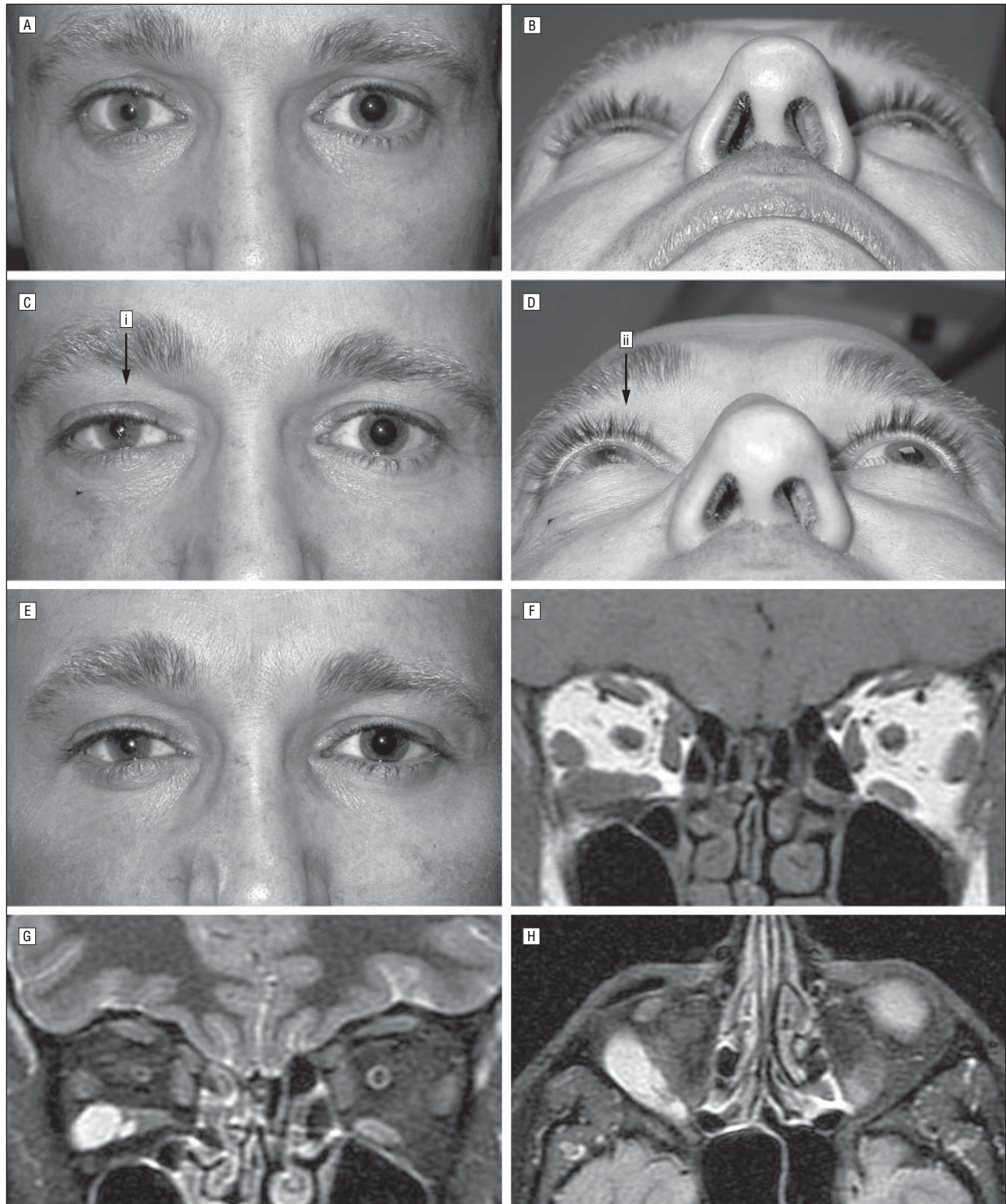
### CASE 4

A 36-year-old man requested treatment for right volume deficiency following enucleation as a result of previous globe injury. Previous surgery included a 20-mm orbital ball implant and a regular-sized Medpor (Porex Surgical, Newman, Georgia) enophthalmic floor implant; however, volume deficiency persisted with a deep right upper eyelid sulcus (**Figure 3A** and **B**). He specifically requested nonsurgical options and, following a fully informed discussion, consented to undergo an orbital Sub-Q injection.

Because patients in the previous 3 cases experienced discomfort and vasovagal symptoms immediately following injection, I performed a peribulbar injection of 0.5-mL 0.5% bupivacaine with 1:200 000 epinephrine through an inferotemporal transcutaneous approach, prior to injecting orbital Sub-Q, to minimize any potential oculocardiac reflex symptoms following intraconal injection. Deep orbital Sub-Q (2 mL) was administered approximately 15 minutes after local anesthetic injection. The procedure was well tolerated with no vasovagal symptoms or discomfort. The patient was observed for an hour and discharged feeling completely well. A reduction of 2 mm in enophthalmos and restoration of upper eyelid sulcus volume was seen immediately after injection (**Figure 3C** and **D**) and at the 5-month follow-up (**Figure 3E**). Magnetic resonance imaging arranged at 9 months after the patient expressed concern of mild orbital volume loss demonstrated the presence of a single bolus of Sub-Q in the right inferotemporal quadrant, bright on T2-STIR and the same intensity as extraocular muscle on T1 images, extending from the equator of the orbital implant to near the orbital apex (**Figure 3F-H**). Volumetric analysis based on coronal and axial cuts estimated the remaining volume of Sub-Q to be approximately 1.6 mL.

### CASE 5

An 18-year-old woman requested treatment for left volume deficiency following enucleation at the age of 5 years as a result of a motor vehicle crash that resulted in orbital trauma. She had undergone a left 20-mm hydroxyapatite orbital implant procedure 2 years prior; however, following an episode of postoperative vomiting, she developed a secondary orbital hemorrhage that displaced the orbital implant both anteriorly and infero-



**Figure 3.** Images for a 36-year-old male patient in case 4. A, Right orbital volume deficiency with a deep right upper eyelid sulcus. B, Right enophthalmos. C and D, A 2-mm reduction in enophthalmos and restoration of upper eyelid sulcus volume at the 5-month follow-up. E, Stable reduction in enophthalmos and restoration of upper eyelid sulcus volume at the 9-month follow-up. F, Magnetic resonance image at 9 months demonstrating the presence of a single bolus of Sub-Q in the right inferotemporal quadrant with the same intensity as extraocular muscle on T1 image. G, Bright on T2-STIR coronal image. H, Extending from the equator of the orbital implant to near the orbital apex on T2-STIR axial image.

temporally. This resulted in exposure, requiring implant removal. The implant was reinserted as a secondary-stage procedure without any postoperative complications, but the patient once again experienced postoperative nau-

sea and vomiting and sought nonsurgical options thereafter. Because of her previous experience, deep orbital Sub-Q was planned in the operating room under mild sedation. At the time of the procedure, the patient con-

tinued to feel anxious despite receiving 2-mL intravenous midazolam. A further 2-mL intravenous midazolam (total, 4 mL) was administered before proceeding with a peribulbar injection of 0.5-mL local anesthesia with epinephrine. A 2-mL deep orbital Sub-Q injection was administered. The procedure was well tolerated with no symptoms of nausea or pain. The patient remained well, and a 2-mm reduction in enophthalmos was seen along with fullness in her left upper eyelid and subbrow sulcus. This result remained stable at the 6-month follow-up.

## RESULTS

Orbital volume enhancement and reduction in enophthalmos of 2 mm following a 2-mL injection was immediately achieved in all primary injections. Repeat 2-mL injections for further volume enhancement did not achieve a further 2 mm in reduction of enophthalmos. However, of note was a significant esthetic improvement in upper eyelid sulcus volume and skin fold. The procedure was well tolerated with complications occurring in 2 patients who developed vasovagal symptoms and signs lasting up to 3 hours and postoperative pain in 1 of these 2 patients, which developed overnight and lasted 48 hours. Reduction in enophthalmos was up to 50% at 8 to 12 months. One patient required hyaluronidase for migrating gel, which caused lower eyelid swelling. One patient required orbital magnetic resonance imaging 9 months following injection, and volumetric analysis based on coronal and axial cuts estimated the remaining volume of Sub-Q to be approximately 1.6 mL, a 20% reduction.

## COMMENT

This small case series suggests the safety and tolerability of Sub-Q into the intraconal and extraconal orbital cavity. In the age of nonsurgical facial rejuvenation, the use of fillers is ideal for orbital volume enhancement in anophthalmic or sighted orbits. The ideal characteristics of soft-tissue fillers include acceptable longevity, biocompatibility, low risk of migration, a minimal adverse event profile, and a reasonable cost-benefit ratio.<sup>11</sup>

A study has demonstrated the use of calcium hydroxylapatite (Radiesse; BioForm Medical, San Mateo, California) in orbital volume replacement for sunken socket syndrome in nonsighted orbits and provided short-term follow-up data of approximately 3 months.<sup>5</sup> This appears to be well tolerated; however, no mechanism exists to dissolve the product should it prove to be undesirable, and it appears to elicit a greater postinjection inflammatory response in comparison with Restylane in terms of early local edema. The authors reported an initial reduction of enophthalmos of greater than 1 mm for every 1 mL of injection for at least a few months.

Orbital volume enhancement with autologous fat transfer by both intraconal and extraconal and periorbital injections has been reported.<sup>12,13</sup> Disadvantages were that 2 procedures were required; it was difficult to predict how long the enhancement would last, requiring multiple treatments; and there was a potential for inflammation.

Although Q-Med provided an 18-gauge needle to inject Sub-Q, minimizing altering stability of the product due to its large particle size, this is largely based on the indications of cheek or chin injection. Accordingly, I opted for a narrower 25-gauge needle to minimize the discomfort of the transcutaneous injection and the potential orbital complications of passing a wider-bore needle trans-orbitally.

After observing discomfort and vasovagal symptoms in previous cases, for case 4 I performed a peribulbar injection of local anesthesia prior to orbital Sub-Q to minimize any potential oculocardiac reflex symptoms following intraconal injection. It is most likely that the vasovagal symptoms, including nausea, following orbital Sub-Q injection are due to stretching of the extraocular muscles following intraconal injection. It is well known that transient oculocardiac-reflex bradycardia can occur during traction on extraocular muscles.<sup>14</sup> Prolonged bradycardia for 36 hours following secondary orbital implant has been described despite blood pressure returning to normal levels by 24 hours.<sup>15</sup> It is possible that a sudden stretch of the extraocular muscles may explain a similar type of oculocardiac reflex following intraconal injection. Although these data do not establish this, the absence of such a response following a prior local anesthetic injection may suggest that this effect can be eliminated. Furthermore, that the response did not occur while the anesthetic gradually wore off suggests that this phenomenon was related to sudden changes of stretch to the extraocular muscles or possibly orbital volume. It is interesting that this response did not occur in case 1 in a sighted orbit. It is possible that following previous orbital implant surgery, the extraocular muscles are already stretched and more sensitive to any further change.

I have resisted tabulating Hertel measurements because a 2-mm reduction of enophthalmos was not achieved in all injections, only usually in primary injections and not in subsequent injections for further volume enhancement. The product is not injected solely intraconally and the benefit of volume enhancement is not simply for reduction in enophthalmos but also for fullness of the upper eyelid sulcus and the lower eyelid.

In conclusion, this small case series suggests that this procedure is safe and well tolerated. Products such as Restylane offer the added advantage of being easily dissolved with hyaluronidase should any early complications occur. This is a novel procedure, and based on experience with orbital volume augmentation using various materials by injection or direct placement, the excellent adverse-effect profile of hyaluronic gel products, and substantial experience in facial injections, there is reason to expect orbital injections to be safe. However, it is not known whether the unique anatomy and physiology of the orbit might lead to site-specific complications of hyaluronic-acid gel injection. Careful follow-up and frank, expedient reporting of any complications are appropriate practices for novel uses of existing medications, and controlled clinical trials will best characterize the long-term success and safety profile of orbital hyaluronic-acid gel injection.

**Submitted for Publication:** July 16, 2007; final revision received September 16, 2007; accepted September 17, 2007.

**Correspondence:** Raman Malhotra, FRCOphth, Corneo-Plastic Unit, Queen Victoria Hospital, Holtye Road, East Grinstead RH19 3DZ, West Sussex, England (malhotraraman@hotmail.com).

**Financial Disclosure:** None reported.

## REFERENCES

1. Hicks CR, Morrison D, Lou X, Crawford GJ, Gadajtsy A, Constable IJ. Orbital implants: potential new directions. *Expert Rev Med Devices*. 2006;3(6):805-815.
2. Bonavolonta G, Tranfa F, Salicone A, Strianese D. Orbital dermis-fat graft using periumbilical tissue. *Plast Reconstr Surg*. 2000;105(1):23-26.
3. Donofrio L. Technique of periorbital lipoaugmentation. *Dermatol Surg*. 2003;29(1):92-88.
4. Schittkowski MP, Guthoff RF. Injectable self inflating hydrogel pellet expanders for the treatment of orbital volume deficiency in congenital microphthalmos: preliminary results with a new therapeutic approach. *Br J Ophthalmol*. 2006;90(9):1173-1177.
5. McMullan TFW, Burroughs JR, Anderson RL, McCann JD, Vagefi MR. Radiesse (injectable calcium hydroxyapatite) as orbital volume replacement for sunken socket syndrome [abstract 103]. Presented at: joint meeting of the European Society of Ophthalmic Plastic and Reconstructive Surgery and British Oculoplastic Surgery Society; 2006; London, England.
6. Soparkar CN, Patrinely JR, Tschen J. Erasing restylane. *Ophthalm Plast Reconstr Surg*. 2004;20(4):317-318.
7. Lowe NJ, Grover R. Injectable hyaluronic acid implant for malar and mental enhancement. *Dermatol Surg*. 2006;32(7):881-885.
8. Belmontesi M, Grover R, Verpaele A. Transdermal injection of restylane SubQ for aesthetic contouring of the cheeks, chin, and mandible. *Aesthetic Surg J*. 2006;15(suppl):S8-S34.
9. Coleman SR, Grover R. The anatomy of the aging face: volume loss and changes in 3-dimensional topography. *Aesthetic Surg J*. 2006;15(suppl):S4-S9.
10. Grover R. Optimizing treatment outcome with restylane SubQ: the role of patient selection and counseling. *Aesthetic Surg J*. 2006;15(suppl):S18-S1.
11. Jacovella PF. Calcium hydroxylapatite facial filler (Radiesse): indications, technique, and results. *Clin Plast Surg*. 2006;33(4):511-3.
12. Hunter PD, Baker SS. The treatment of enophthalmos by orbital injection of fat autograft. *Arch Otolaryngol Head Neck Surg*. 1994;120(8):835-839.
13. Olver JM, Tumuluri K. Coleman fat transfer use in orbital and periorcular surgery. Presented at: annual meeting of the British Oculoplastic Surgery Society; 2004; Manchester, England.
14. Dagnini G. Intorno ad un riflesso provocato in alcuni emiplegici collo stimolo della cornea e colla pressione sul bulbo oculare. *Bull Soc Med Bologna*. 1908;8:380.
15. Burns S. Prolonged bradycardia after secondary orbital implant. *Orbit*. 2006;25(1):55-56.

## From the Archives of the Archives

The extraction of teeth rarely causes purulent inflammation of the orbital cellular tissues. Feuer, in his paper published in 1892, reviews ten cases. Hirsch, in 1894, was able to collect twenty-five cases. He remarked, however, that in most cases there had been caries of the teeth, and frequently the extraction had led to improvement in the orbital condition, or even to complete recovery from it. Hirsch considers as pure cases only those of Tetzner, Vossius, Burnett, and Fage, adding three observations of his own, in which the extraction of a carious tooth was followed by septic infection and the speedy development of a retrobulbar phlegmon.

Our case is of the same sort. . . . In our case the infective matter passed from the alveolar process into the antrum, and thence through the venous anastomoses into the orbit. In the process the purulent masses rarefied the wall of the nose, and on the sixth day escaped through the right nostril.

**Reference:** Hallauer O. A case of phlegmon of the orbit after extraction of a tooth. *Arch Ophthalmol*. 1902;31:230,234.